



The Role of Stereotactic Radiotherapy for the Treatment of Melanoma and Renal Cell Carcinoma Brain Metastases

Melike PEKYÜREK VARAN, Gökhan YAPRAK, Emriye ALGÜL, Duygu GEDİK, Naciye IŞIK

Department of Radiation Oncology, University of Health Sciences, Kartal Dr. Lütfi Kırdar City Hospital, İstanbul-Türkiye

OBJECTIVE

The best radiotherapeutic approach for brain metastasis (BM) is highly controversial. Compared to Whole-brain radiotherapy, the stereotactic radiotherapy (SRT) technique allows for focused ablative doses to target lesions. We aim to present our clinical experience with SRT as a treatment option for radioresistant BM in melanoma and renal cell carcinoma (RCC).

METHODS

We identified 46 BM from radioresistant histologies (26 melanoma and 20 RCC) treated with SRT in our clinic between 2010 and 2020 in 29 patients (18 melanoma and 11 RCC). The robotic linear accelerator-based CyberKnife system was used to administer SRT.

RESULTS

SRT was performed in a median of 2 fractions, and the median dose was 20 Gy. The median follow-up was 8 months. Median overall survival after SRT was 8 months, and 1- and 2-year survival rates were 37.9 and 14.2%, respectively. Median local progression-free survival (LPFS) was not reached, and 1- and 2-year LPFS were both 83.4%. Median distant brain progression-free survival (DBPFS) was 14 months, and 1- and 2-year DBPFS rates were 54.2 and 23.2%, respectively. Radionecrosis occurred in 2 metastases (4.3%).

CONCLUSION

SRT is a valuable treatment option for RCC and melanoma brain metastases with reasonable local and distant brain control and limited toxicity.

Keywords: Brain metastasis; melanoma; radioresistant; renal cell carcinoma; stereotactic radiotherapy.

Copyright © 2023, Turkish Society for Radiation Oncology

INTRODUCTION

Brain metastasis (BM) is the most frequent intracranial malignancy, and it is predicted to occur 10 times more frequently than primary malignant brain tumors.[1]

Of all tumors, melanoma has the greatest propensity to metastasize to the brain.[2] It is the third most common cause of BM, responsible for 6%–11% of all metastatic brain lesions.[3–7] On the other hand,

renal cell carcinoma (RCC), another radioresistant histology like melanoma, is responsible for 2–6% of BM cases.[3,4,7,8]

Whole-brain radiotherapy (WBRT) has traditionally been considered as the standard radiotherapeutic approach for BM of all histologies. Whereas the emergence of advanced radiotherapy techniques like stereotactic radiotherapy (SRT) provides the opportunity to deliver focused ablative doses to target lesions. The best

Received: November 18, 2022

Accepted: August 21, 2023

Online: September 11, 2023

Accessible online at:
www.onkder.org

Dr. Melike PEKYÜREK VARAN

Sağlık Bilimleri Üniversitesi,

Kartal Dr. Lütfi Kırdar Şehir Hastanesi,

Radyasyon Onkolojisi Kliniği,

İstanbul-Türkiye

E-mail: melikepekyurek@gmail.com



radiotherapeutic approach for BM is a highly debated topic since there are criticisms of neurocognitive function and quality of life deterioration for WBRT and distant intracranial progression for SRT.[9–11]

In this controversial issue, BM in melanoma and RCC have unique significance as they have been considered to be “radioresistant” to conventional fractionated radiotherapy. However, SRT delivers high fraction doses, so it provides a radiobiological advantage to counter the radioresistance of tumors. But BM of radioresistant histologies was underrepresented in phase III studies, and there are no randomized data comparing radiotherapeutic options, particularly for radioresistant BM. Many retrospective data prove that SRT is a safe and effective treatment for radioresistant BM.[12–15]

In this article, we aim to present our clinical experience with SRT as a treatment option for radioresistant BM of melanoma and RCC.

MATERIALS AND METHODS

In this retrospective study, we reviewed data from patients with radioresistant BM melanoma or RCC treated with SRT in our department between 2010 and 2020. All of the patients were ≥ 18 years old, and their Karnofsky performance scale (KPS) score was ≥ 60 . Patients had at least one pre-SRT and one post-SRT brain magnetic resonance imaging (MRI) evaluation.

Informed consent was obtained from all the patients. The declaration of Helsinki[16] was adequately addressed, and the study was approved by the Local Ethical Committee of our hospital (register number: 2020/514/186/9).

Radiotherapy Technique and Treatment Planning

All patients were treated with a robotic LINAC-based SRT, the CyberKnife system (Accuray Inc., Sunnyvale, CA, USA). Patients were positioned supine and immobilized using a noninvasive thermoplastic head mask prepared for the simulation computerized tomography (CT) scan. Contrast-enhanced MRI and CT scans with 1 mm slice thickness were utilized. All treatment planning procedures were performed using dedicated inverse planning software, Multiplan (Accuray®). An exemplary patient treatment plan is shown in Figure 1.

Gross tumor volume (GTV) was defined as the area enhanced on post-contrast T1-weighted images, and a circumferential 1mm margin was added to define the planning target volume (PTV). Doses were prescribed to 70%–94% isodose lines, so 95% of PTV and 99% of

GTV were aimed at achieving prescription dose coverage. AAPM TG 101 report recommendations were used to assess organ at-risk doses.[17] The dose and fractionation schedule were determined considering the PTV volume and proximity of critical structures.

Follow-Up

Patients were followed up regularly at 1–3 month intervals or as clinically indicated. During the follow-up visits, patients were evaluated clinically by history and physical examination and radiologically by contrast-enhanced brain MRI. Additional MR spectroscopy and MR perfusion were performed in cases where tumor progression or radionecrosis distinction was uncertain. Local control evaluation was performed based on the Response Evaluation Criteria in Solid Tumors Version 1.1 (RECIST v1.1).[18]

Statistics

Local progression-free survival (LPFS), distant brain progression-free survival (DBPFS), and overall survival (OS) were defined as the time from the 1st day of SRT to the detection of the local failure, the first distant brain failure, and the death from any cause, respectively. Survival results were evaluated with the Kaplan–Meier method. The effects of the variables on survival outcomes were evaluated by performing univariate and multivariate analyses using Cox models and log-rank tests. A $p < 0.05$ was accepted as statistically significant. All statistical analyses were performed using SPSS 20.0 software (The Statistical Package for the Social Sciences, 20.)

RESULTS

Patient and Treatment Characteristics

We reviewed the data on BM cases treated with SRT in our clinic between 2010 and 2020. We identified 46 BM from radioresistant histologies (26 melanoma and 20 RCC) in 29 patients. Among these patients, 19 were male and 10 were female, and the median age at the time of SRT was 63 years. The median KPS score was 90 (range 70–100). The primary histology was melanoma in 18 patients (62%) and RCC in 11 patients (38%). WBRT was received by 4 patients (14%) before SRT.

SRT was performed in 2 fractions (range 1–5) to a median prescription dose of 20 Gy (range 15–25.5), which is biologically equivalent to a dose of 52.8 Gy (range 28.8–70.4). The SRT plan quality indexes were as follows: median conformity index 1.18 (range 1.03–5.48), new conformity index 1.26 (range 1.11–5.59), and homogeneity index 1.12 (range 1.06–1.56). The

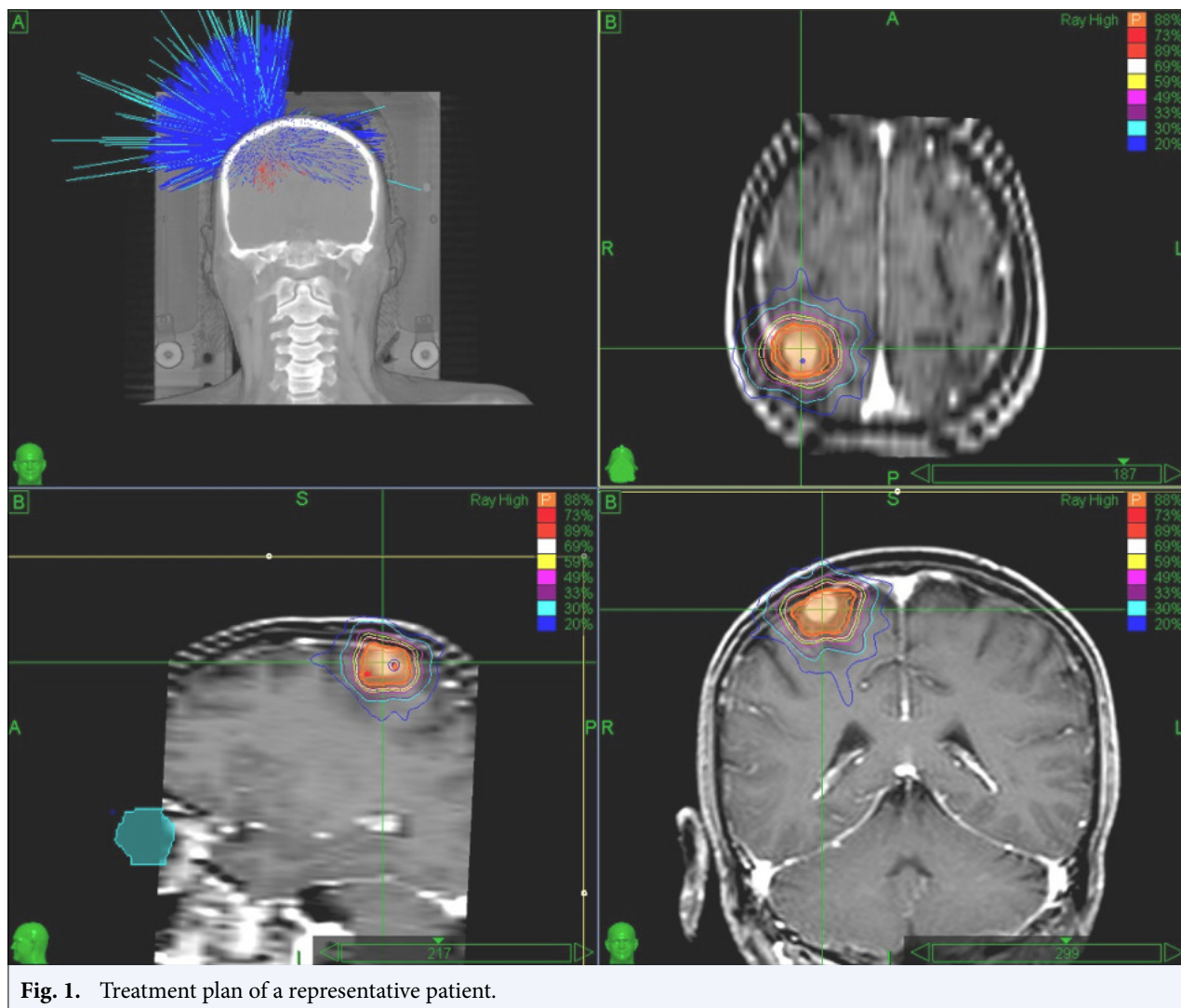


Fig. 1. Treatment plan of a representative patient.

median maximum diameter and volume of lesions were 15 mm (range 5–64) and 1.44 mL (range 0.05–36.2), respectively. The median target volume (PTV) was 2.58 mL (range 0.12–40.1). The number of BM patients treated with SRT was 1 in 18 patients (62.1%), 2 in 5 patients (17.2%), and 3 in 6 patients (20.7%). The median total intracranial tumor volume was 4.61 mL (range 0.05–36.2). The patient characteristics and treatment parameters are summarized in Table 1.

Clinical Outcomes

The median follow-up was 8 months (range 1–101). At the time of analysis, four patients (13.8%) were alive. Median OS after SRT was 8 months (95% CI: 5.4–10.6), and 1- and 2-year survival rates were 37.9 and 14.2%, respectively. According to RECIST, complete response was observed in 10 lesions (21.7%),

partial response in 12 lesions (26.1%), stable disease in 19 lesions (41.3%), and progression in 5 lesions (10.9%) during the first 3 months after SRT. The median LPFS was not reached, and the 1- and 2-year LPFS were both 83.4%. At the time of analysis, 15 patients (52%) had distant brain failure. Median distant brain progression-free survival was 14 months (95% CI: 4.9–23.1), and 1- and 2-year DBPFS rates were 54.2 and 23.2%, respectively. The OS, LPFS, and DBFS curves are represented in Figure 2.

The LPFS-related variables were analyzed using univariate analysis. There was no statistically significant relationship with lesion histology, lesion location, PTV coverage, or BED10. There was a trend towards better LPFS for patients with smaller tumor (GTV) volumes ($p=0.06$). Smaller target (PTV) volumes were associated with statistically significant better LPFS ($p=0.045$).

Table 1 Patient characteristics and treatment parameters

	n	%
Number of patients		
29	18 melanoma	
	11 RCC	
Number of lesions		
46	26 melanoma	
	20 RCC	
Number of BM treated with SRT		
1	18	62.1
2	5	17.2
3	6	20.7
Lesion maximum diameter (mm)	15	(5–64)
GTV volume (mL)	1.44	(0.05–36.2)
PTV volume (mL)	2.58	(0.12–40.1)
Lesion location		
Supratentorial	41	89.2
Infratentorial	5	10.8
Total intracranial tumor volume (mL)	4.61	(0.05–36.2)
SRT dose (Gy)	20	(15–25.5)
SRT fraction	2	(1–5)
BED ₁₀	52.8	(28.8–70.4)
Conformity index	1.18	(1.03–5.48)
New conformity index	1.26	(1.11–5.59)
Homogeneity index	1.12	(1.06–1.56)
Isodose	89	(64–94)
GTV coverage (%)	99.55	(95.4–100)
PTV coverage (%)	96.7	(86.6–99.3)
SRT response at first control		
Complete response	10	21.7
Partial response	12	26.1
Stable	19	41.3
Progression	5	10.9

Values are presented as number (%) or median (range). RCC: Renal cell cancer; BM: Brain metastases; SRT: Stereotactic radiotherapy; GTV: Gross tumor volume; PTV: Planning target volume; BED: Biologically effective dose

When we focused on prior therapies for BM, there was a trend toward worse LPFS for patients with a history of WBRT ($p=0.096$). On multivariate analysis, none of the investigated variables was significant.

On univariate analyses for DBPFS, there was no statistically significant relationship between the number of BM treated with SRT, total intracranial tumor volume, or lesion histology. However, freedom from local progression ($p=0.055$) and KPS score ($p=0.054$) showed trends for positive associations with DBPFS. Patients with a prior history of WBRT showed statistically significant poor DBFS ($p=0.001$). On multivariate analysis, none of the investigated variables was significant.

On univariate analyses for OS, there was no statistically significant relationship with the number of

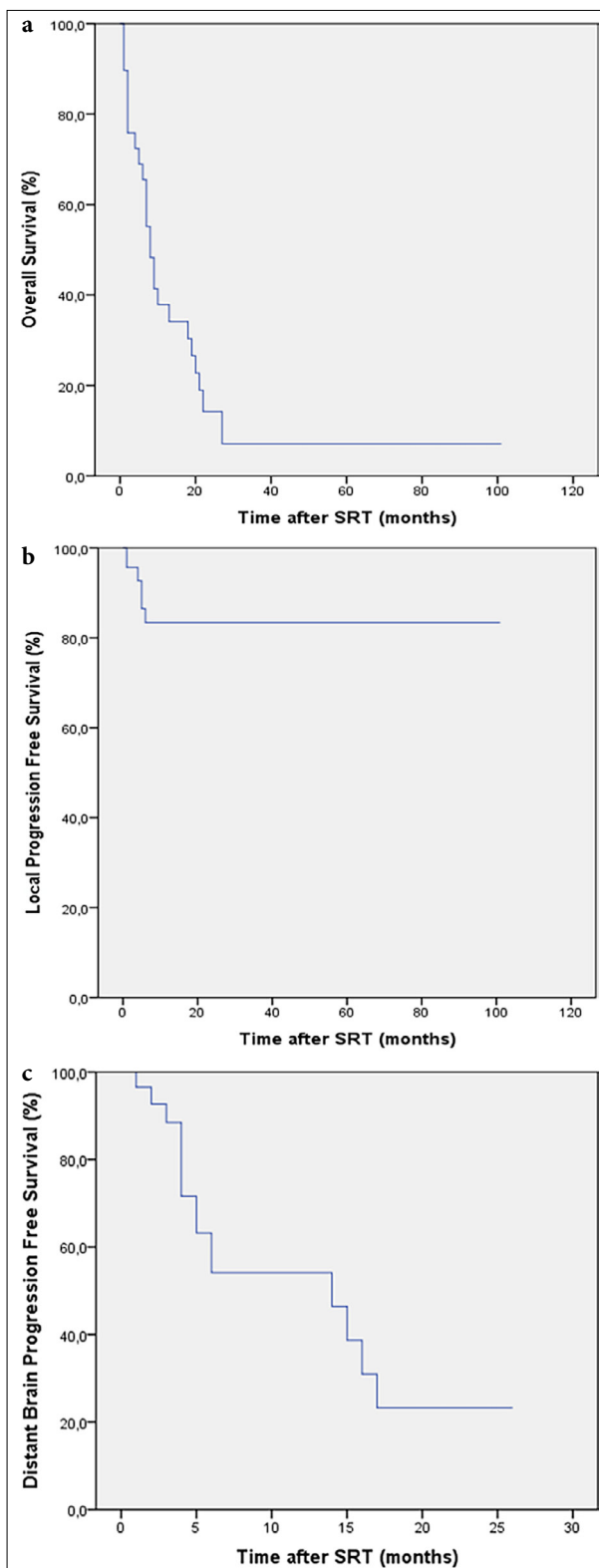


Fig. 2. (a) Overall survival curve, (b) Local control curve, (c) Distant brain control curve. SRT: Stereotactic radiotherapy.

Table 2 Univariate analyses results

Endpoint	Variable	p
LPFS	Lesion histology	0.954
	Lesion location	0.338
	PTV coverage	0.231
	BED ₁₀	0.688
	Prior history of WBRT	0.096
	GTV volume	0.06
DBPFS	PTV volume	0.045
	Number of BM treated with SRT	0.124
	Total intracranial tumor volume	0.340
	Lesion histology	0.501
	Freedom from local progression	0.055
OS	Karnofsky Performance Status Score	0.054
	Prior history of WBRT	0.001
	Number of BM treated with SRT	0.670
	Gender	0.286
	Karnofsky Performance Status Score	0.640
	Prior history of WBRT	0.223
	Freedom from local progression	0.380
	Freedom from distant brain progression	0.233
	Lesion histology	0.032
	Total intracranial tumor volume	0.014

LPFS: Local progression-free survival; PTV: Planning target volume; BED: Biologically effective dose; WBRT: Whole brain radiation therapy; GTV: Gross tumor volume; DBPFS: Distant brain progression-free survival; OS: Overall survival; BM: Brain metastases; SRT: Stereotactic radiotherapy

BM treated with SRT, gender, KPS score, prior history of WBRT, freedom from local progression, or distant brain progression. When we focused on the histologic type, patients with melanoma showed poorer OS as compared with patients with RCC (p=0.032). Patients with small total intracranial tumor volumes showed statistically increased OS (p=0.014). On the multivariate analysis, total intracranial volume remained significant (p=0.046, exp (B):1).

Univariate analyses results are summarized in Table 2.

Toxicities

Radionecrosis occurred in 2 metastases (4.3%), both in melanoma patients. Four cases experienced new-onset seizures, and one case reported occasional headaches following SRT; all were melanoma patients.

DISCUSSION

The best radiotherapeutic approach for BM is highly controversial. While WBRT has traditionally been considered the standard radiotherapeutic approach for BM of all histologies, the SRT technique has emerged that allows for focused ablative doses to target lesions.

The role of SRT in BM treatment has been the subject of several randomized trials. Two landmark Phase III randomized trials comparing SRS and SRS+ WBRT in patients with 1–3 BM established stereotactic radiosurgery as the standard of care, replacing WBRT due to better preservation of cognitive function without compromising OS.[9,11] However, radioresistant histologies are underrepresented in both trials. The trial by Chang et al.[9] terminated before the planned sample size with the recruitment of only 58 due to the detection of a high probability (96%) that patients in the SRS plus WBRT arm were significantly more likely to show a decline in cognitive function, and among these 58 patients, there were 11 patients with melanoma and RCC primary histology, including 6 in the SRS and 5 in the SRS+WBRT arm. On the other hand, Brown et al.[11] published their results with 213 patients; however, melanoma and RCC histologies were both underrepresented and not equally distributed among study arms (a total of 3.6% in the SRS arm and 12.9% in the SRS+WBRT arm). It is unclear whether the conclusion drawn from these RCTs would be valid for radioresistant BM, and to date, no phase III clinical trials have been published specifically investigating the role of SRT in radioresistant BM. A Phase II trial of radiosurgery for one to three newly diagnosed brain metastases (n=36) from RCC, melanoma, and sarcoma reported high intracranial failure rates (48.3% of patients by 6 months) with the omission of WBRT.[19] In the current study, we aimed to present our results on this highly debated topic regarding the role of SRT in the BM of radioresistant histologies.

At the culmination of our study, both 1- and 2-year LPFS rates were 83.4%, and 1- and 2-year DBFS rates were 54.2 and 23.2%, respectively. We found our LPFS and DBFS results to be markedly better than previous studies investigating similar patient groups to our study. Lo et al.[20] published their results of SRS for patients with 1–4 radioresistant BM and reported 67.9% 1-year local control and 40.2% 1-year free-from-distant-brain-failure rates. Lwu et al.[21] also published their institutional results using SRS for treating RCC and melanoma brain metastases and reported 84% 1-year and 61% 2-year local control rates. Compared to the two studies above that used more subjective measurement methods for local control, we utilized a volumetric measurement of tumor size in our methodology and used RECIST criteria to assess local control. This difference in LPFS and DBPFS seen between our study and other previously reported series may also be explained by the possible more frequent utilization of

modern systemic agents recently shown to have central nervous system activity in our cohort.[22,23] However, the detailed systemic therapy records needed to support this argument were unavailable for our patients, and this is a limitation of our study.

Consistent with our univariate analysis results, Lesueur et al.[15] reported that histology had no significant effect on LPFS, but large tumor volume was a statistically significant predictive factor for local failure. On the opposite, contrary to our results, Lwu et al.[21] defined RCC pathology as a predictor of a better response to SRS. However, they also found small tumor volume to be a predictive factor of response to SRS and reported that lesions with RCC pathology had smaller tumor volumes. Therefore, they argued that the effect of histology on the response to SRS may be the result of a smaller tumor volume. Lo et al.[20] also reported RCC histology to be a predictor of better local control compared to melanoma. They reported that ten of 14 RCC patients received sunitib, a CNS active agent, which may have a contributing effect on better local control outcomes. After this publication by Lo et al. in 2011, many CNS active agents have been started to be used in melanoma, and new CNS active agents besides sunitib have been approved for RCC treatment. Therefore, the confounding effect of systemic agents has gained even more importance in recent melanoma and RCC BM studies, including our study.

In our study, 4 patients had a previous history of WBRT, and SRT was applied as salvage therapy. These patients showed statistically significant poor DBPFS and a trend towards poor LPFS. Poor DBFS outcomes could be explained by the presence of extensive intracranial disease spread at baseline. Although lesions other than salvage-SRT were considered to be under control and therefore salvage-SRT was not needed, highly resistant tumor strains may have remained dormant and caused future recurrence. The trend towards poor LPFS could be explained by possible aggressive tumor features leading to resistance to salvage SRT as well as to the previous WBRT.

The median OS of our cohort after SRT was 8 months. Patients with small total intracranial tumor volumes ($p=0.014$) and patients with RCC ($p=0.032$) showed statistically increased OS. However, previous studies from Lo et al. and Lesueur et al.[15,20] reported that histology had no statistically significant impact on OS. When we reviewed our data, we found that patients with RCC had a lower mean total intracranial tumor volume, and multivariate analysis revealed that histology is not a prognostic factor for OS. We conclude that the ef-

fect of histology on OS detected in the univariate analysis may be the result of the confounding effect of lower total intracranial tumor volume. In fact, OS is a complex endpoint for a study investigating treatment options for brain metastases because, apart from the factors related to brain metastases and their treatment, there are many confounding factors for OS, such as extracranial systemic disease burden and systemic treatments.

Limitations of the Study

Limitations of our study include a retrospective design, a small sample size, insufficient systemic treatment records, and a lack of information about the neurocognitive function of patients.

CONCLUSION

SRT is a valuable treatment option for RCC and melanoma brain metastases with reasonable local and distant brain control and limited toxicity.

Peer-review: Externally peer-reviewed.

Conflict of Interest: All authors declared no conflict of interest.

Ethics Committee Approval: The study was approved by the Kartal Dr. Lütfi Kırdar City Hospital Clinical Research Ethics Committee (no: 2020/514/186/9, date: 30/09/2020).

Financial Support: None declared.

Authorship contributions: Concept – M.P.V., G.Y., E.A., D.G., N.I.; Design – M.P.V., G.Y., E.A., D.G., N.I.; Supervision – M.P.V., G.Y., E.A., D.G., N.I.; Funding – G.Y., M.P.V.; Materials – N.I., D.G., E.A.; Data collection and/or processing – N.I., E.A., M.P.V.; Data analysis and/or interpretation – G.Y., D.G., M.P.V.; Literature search – M.P.V., G.Y.; Writing – M.P.V., G.Y.; Critical review – N.I., D.G.

REFERENCES

- Ostrom QT, Wright CH, Barnholtz-Sloan JS. Brain metastases: epidemiology. *Handb Clin Neurol* 2018;149:27–42.
- Sul J, Posner JB. Brain metastases: epidemiology and pathophysiology. *Cancer Treat Res* 2007;136:1–21.
- DeAngelis LM, Posner JB. Intracranial metastases. In: DeAngelis LM, Posner JB, editors. *Neurologic complications of cancer*. New York: Oxford University Press; 2008.
- Counsell CE, Collie DA, Grant R. Incidence of intracranial tumours in the Lothian region of Scotland, 1989–90. *J Neurol Neurosurg Psychiatry*. 1996;61(2):143–50.

5. Fabi A, Felici A, Metro G, Mirri A, Bria E, Telera S, et al. Brain metastases from solid tumors: disease outcome according to type of treatment and therapeutic resources of the treating center. *J Exp Clin Cancer Res* 2011;30(1):10.
6. Stark AM, Stöhring C, Hedderich J, Held-Feindt J, Mehdorn HM. Surgical treatment for brain metastases: Prognostic factors and survival in 309 patients with regard to patient age. *J Clin Neurosci* 2011;18(1):34–8.
7. Nussbaum ES, Djalilian HR, Cho KH, Hall WA. Brain metastases. Histology, multiplicity, surgery, and survival. *Cancer* 1996;78(8):1781–8.
8. Lagerwaard FJ, Levendag PC, Nowak PJ, Eijkenboom WM, Hanssens PE, Schmitz PI. Identification of prognostic factors in patients with brain metastases: a review of 1292 patients. *Int J Radiat Oncol Biol Phys* 1999;43(4):795–803
9. Chang EL, Wefel JS, Hess KR, Allen PK, Lang FF, Kornuth DG, et al. Neurocognition in patients with brain metastases treated with radiosurgery or radiosurgery plus whole-brain irradiation: a randomised controlled trial. *Lancet Oncol* 2009;10(11):1037–44.
10. Soffietti R, Kocher M, Abacioglu UM, Villa S, Fauchon F, Baumert BG, et al. A European Organisation for Research and Treatment of Cancer phase III trial of adjuvant whole-brain radiotherapy versus observation in patients with one to three brain metastases from solid tumors after surgical resection or radiosurgery: quality-of-life results. *J Clin Oncol* 2013;31(1):65–72.
11. Brown PD, Jaeckle K, Ballman KV, Farace E, Cerhan JH, Anderson SK, et al. Effect of radiosurgery alone vs radiosurgery with whole brain radiation therapy on cognitive function in patients with 1 to 3 brain metastases: a randomized clinical trial. *JAMA* 2016;316(4):401–9.
12. Mori Y, Kondziolka D, Flickinger JC, Kirkwood JM, Agarwala S, Lunsford LD. Stereotactic radiosurgery for cerebral metastatic melanoma: factors affecting local disease control and survival. *Int J Radiat Oncol Biol Phys* 1998;42(3):581–9.
13. Jensen RL, Shrieve AF, Samlowski W, Shrieve DC. Outcomes of patients with brain metastases from melanoma and renal cell carcinoma after primary stereotactic radiosurgery. *Clin Neurosurg* 2008;55:150–9.
14. Clarke JW, Register S, McGregor JM, Grecula JC, Mayr NA, Wang JZ, et al. Stereotactic radiosurgery with or without whole brain radiotherapy for patients with a single radioresistant brain metastasis. *Am J Clin Oncol* 2010;33(1):70–4.
15. Lesueur P, Lequesne J, Barraux V, Kao W, Geffrelet J, Grellard JM, et al. Radiosurgery or hypofractionated stereotactic radiotherapy for brain metastases from radioresistant primaries (melanoma and renal cancer). *Radiat Oncol* 2018;13:138.
16. World Medical Association. World Medical Association Declaration of Helsinki: ethical principles for medical research involving human subjects. *JAMA* 2013;310(20):2191–4.
17. Benedict SH, Yenice KM, Followill D, Galvin JM, Hinson W, Kavanagh B, et al. Stereotactic body radiation therapy: the report of AAPM Task Group 101. *Med Phys* 2010;37(8):4078–101.
18. Schwartz LH, Litière S, de Vries E, Ford R, Gwyther S, Mandrekar S, et al. RECIST 1.1-Update and clarification: From the RECIST committee. *Eur J Cancer* 2016;62:132–7.
19. Manon R, O'Neill A, Knisely J, Werner-Wasik M, Lazarus HM, Wagner H, et al; Eastern Cooperative Oncology Group. Phase II trial of radiosurgery for one to three newly diagnosed brain metastases from renal cell carcinoma, melanoma, and sarcoma: an Eastern Cooperative Oncology Group study (E 6397). *J Clin Oncol* 2005;23(34):8870–6.
20. Lo SS, Clarke JW, Grecula JC, McGregor JM, Mayr NA, Cavaliere R, et al. Stereotactic radiosurgery alone for patients with 1-4 radioresistant brain metastases. *Med Oncol* 2011;28:S439–44
21. Lwu S, Goetz P, Monsalves E, Aryaee M, Ebinu J, Laperriere N, Menard C, et al. Stereotactic radiosurgery for the treatment of melanoma and renal cell carcinoma brain metastases. *Oncol Rep* 2013;29(2):407–12.
22. Matsui Y. Current multimodality treatments against brain metastases from renal cell carcinoma. *Cancers (Basel)* 2020;12(10):2875.
23. Eroglu Z, Holmen SL, Chen Q, Khushalani NI, Amaravadi R, Thomas R, et al. Melanoma central nervous system metastases: An update to approaches, challenges, and opportunities. *Pigment Cell Melanoma Res* 2019;32(3):458–69.